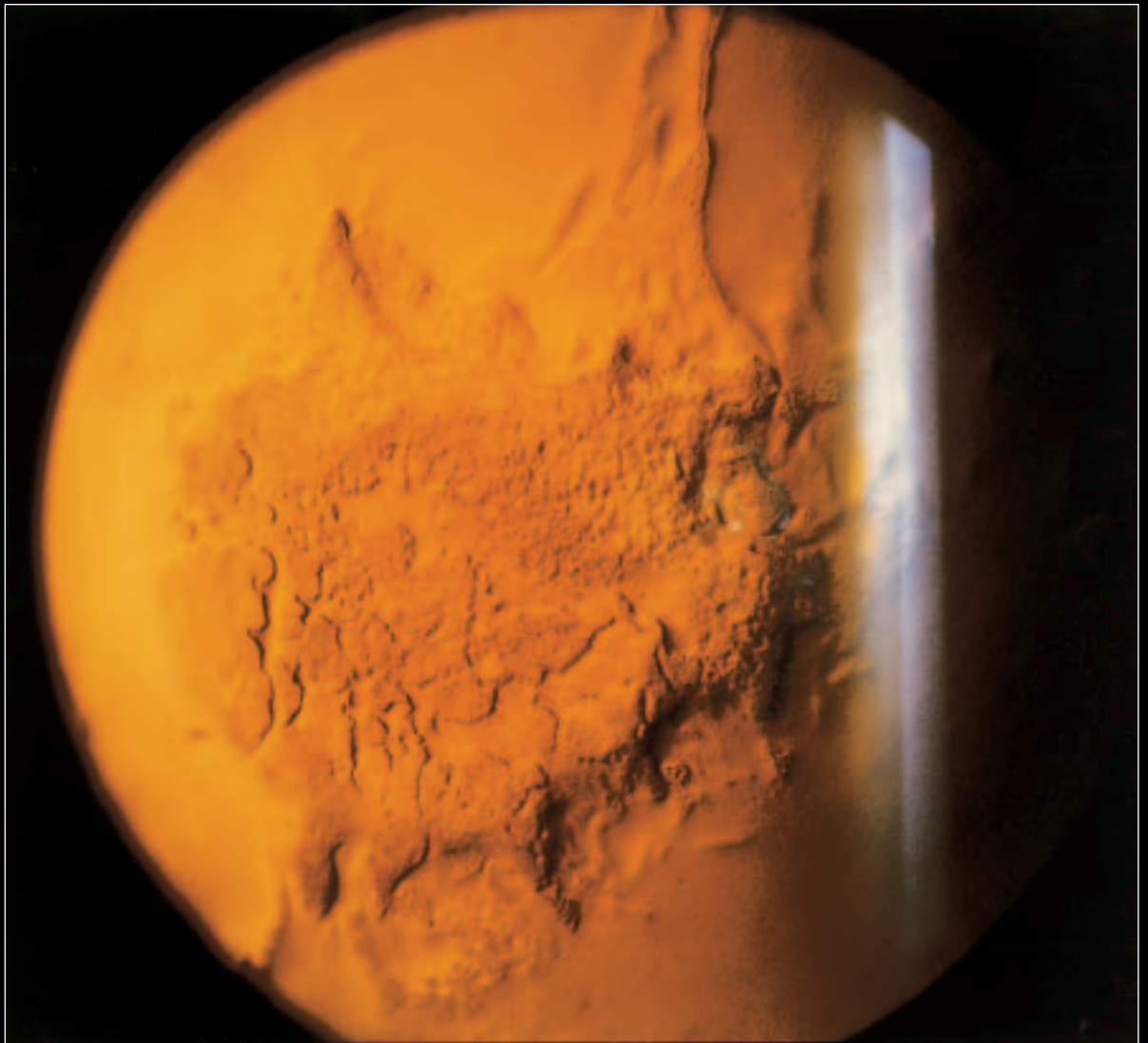


The Journal of Ophthalmic Photography

VOLUME 21 • NUMBER THREE • DECEMBER, 1999



1998 SCIENTIFIC EXHIBIT
FIRST PLACE SLIT LAMP BIOMICROGRAPHY

Cornea Following Applanation Tonometry

Angela Chappell

Flinders Medical Centre, Adelaide, S. Australia

The Journal of Ophthalmic Photography

Volume 21 Number Three

December 1999

JOP INDEX 1978-1998: VOLUMES 1-20


Content Index	70
Subject Index	78
Author Index	83
Advertiser Index	89

IN MEMORIUM

Don Wong, RBP, FOPS 1931-1999	77
-------------------------------------	-----------

LETTER FROM THE EDITOR	68
------------------------------	-----------

INSTRUCTIONS TO AUTHORS	90
-------------------------------	-----------



About the Cover

A good example of getting a great picture when least expected, it also demonstrates why patients should have photos before pressure checks. The embossed appearance of the cornea meant that documentation of the patient's cataracts (the original photographic request) was obviously made difficult. Angela Chappell, Ophthalmic Photographer at Flinders Medical Centre, South Australia made this photograph on a Haag Streit Photo-slit lamp 900 PBQ, 2.5x magnification, on Ektachrome 200 film. The patient's pupils were fully dilated.