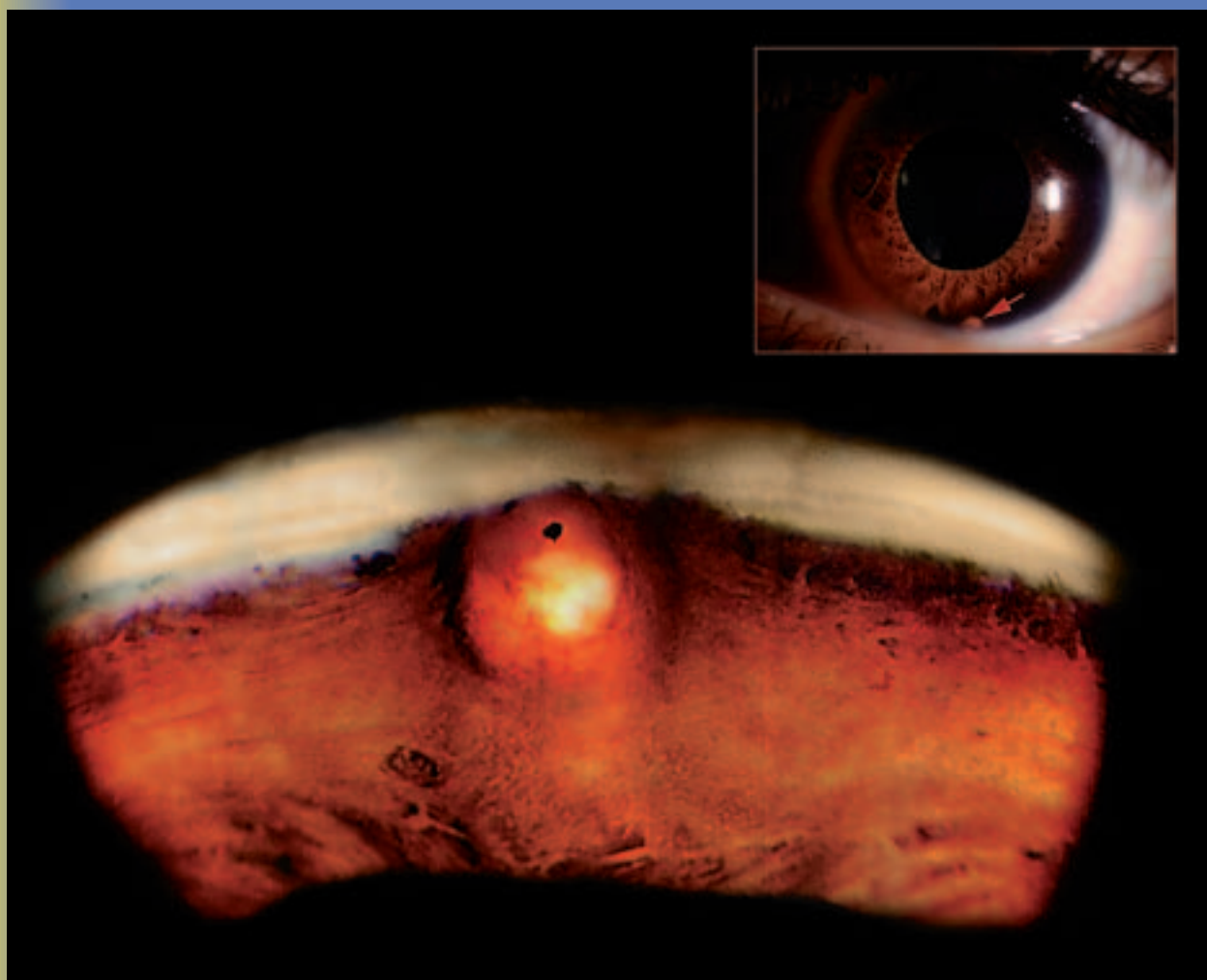


# The Journal of Ophthalmic Photography



VOLUME 20 • NUMBER THREE • DECEMBER, 1998



**1997 SCIENTIFIC EXHIBIT  
FIRST PLACE GONIO PHOTOGRAPHY**

*Iris Cyst*

Marshall E. Tyler, CRA, FOPS

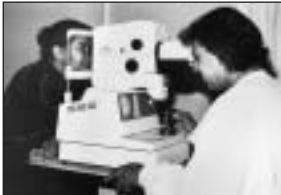Wake Forest University Eye Center, Winston-Salem, NC

# The Journal of Ophthalmic Photography

Volume 20 Number Three

December 1998

## ARTICLES

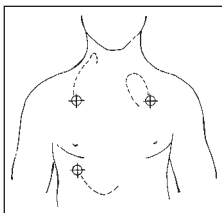


### Diabetic Retinopathy Screening in Remote Australian Communities with Non-Mydriatic Fundus Cameras

Matthew Wade

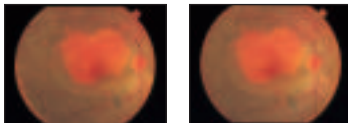
Chris Barry, CRA

Ian McAllister, FRACO, FRACS ..... **80**



### Case Report: Implantable Vascular Access Devices and Fluorescein Angiography

Karen A. Klima, BA, CRA, COMT ..... **84**



### Stereopsis and the Ophthalmic Photographer – A Monocular Technique for Pairing Slides

Lon Dowell, CRA

Sanford Chen, MD ..... **87**

LETTER FROM THE EDITOR ..... 76

LETTERS TO THE EDITOR ..... 78

CALENDAR ..... 79

OPTIMAL DIGESTED ..... 89

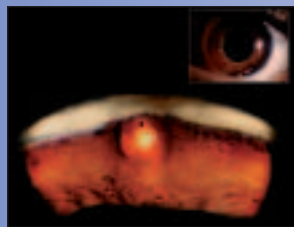
TECHNICAL TACTICS ..... 95

NEW TECHNOLOGY REPORT ..... 96

CERTIFIED RETINAL ANGIOGRAPHERS ..... 98

INSTRUCTIONS TO AUTHORS ..... 100

## About the Cover



The insert, a diffuse illumination slit-lamp photograph, shows the size and location of the cyst. The larger image is a photocomposite of 5 gonio photographs. Original images on a Zeiss photo slit-lamp with Ektachrome film, scanned and composited in Photoshop. Photograph by Marshall E. Tyler, CRA, FOPS.