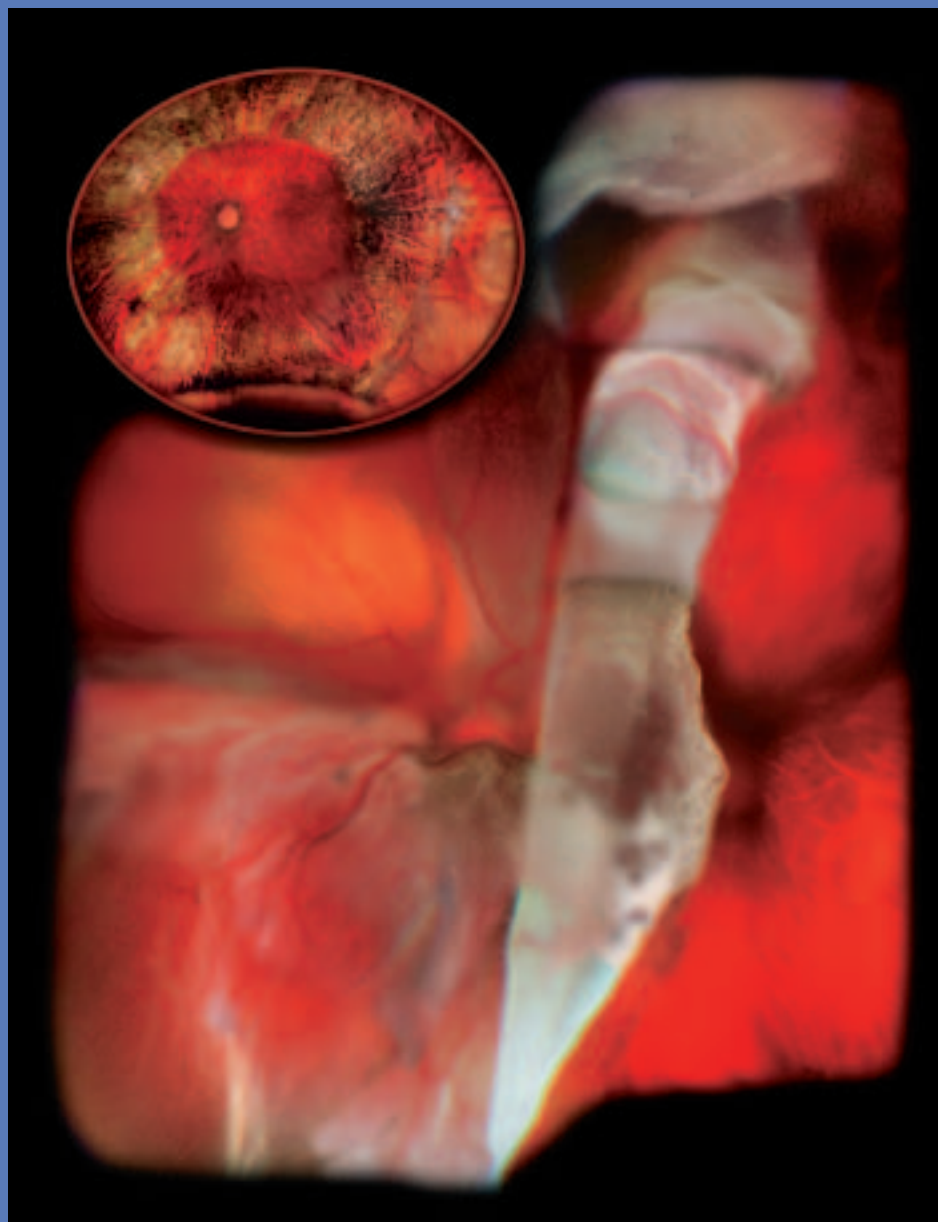


The Journal of Ophthalmic Photography



VOLUME 20 • NUMBER TWO • OCTOBER, 1998



1997 SCIENTIFIC EXHIBIT
FIRST PLACE SPECIAL EFFECTS PHOTOGRAPHY

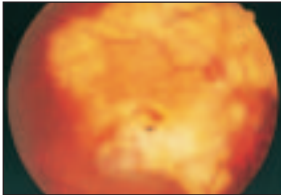
Giant Retinal Tear w/Retinal Detachment w/2 month Post-Op
Marshall Tyler, CRA, FOPS Wake Forest University Eye Center

The Journal of Ophthalmic Photography

Volume 20 Number Two

October 1998

ARTICLES

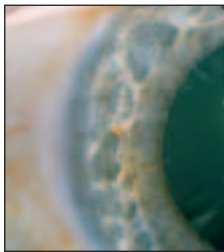


A Task Analysis of Digital Angiography of the Ocular Fundus

Gordon McGregor, CRA, MA **45**

Case Report: Presumed Progressive Choroidal Osteoma With Associated Subretinal Neovascularization

Chris Barry, CRA **54**
Ian J. Constable, FRACO, FRACS

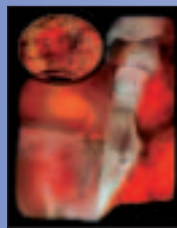

Case Report: Ocular Ischemic Syndrome

Michael P. Kelly **57**

LETTER FROM THE EDITOR	40
LETTERS TO THE EDITOR	42
FINANCE 101	53
PATIENT CARE CORNER	60
CERTIFIED RETINAL ANGIOGRAPHERS	62
OPTIMAL DIGESTED	63
CALENDAR	66
INSTRUCTIONS TO AUTHORS	67
NEW TECHNOLOGY REPORT	70

About the Cover



This composite image of a 64 year old male before (210 degree retinal attachment) and after surgery (2 weeks post-op) was created using Photoshop. Approximately fifteen images from a Topcon 50 degree camera were combined digitally to form each of the two images in this FundusMap. It won First Place in the 1997 OPS Scientific Exhibit in the *Special Effects Photography* category.