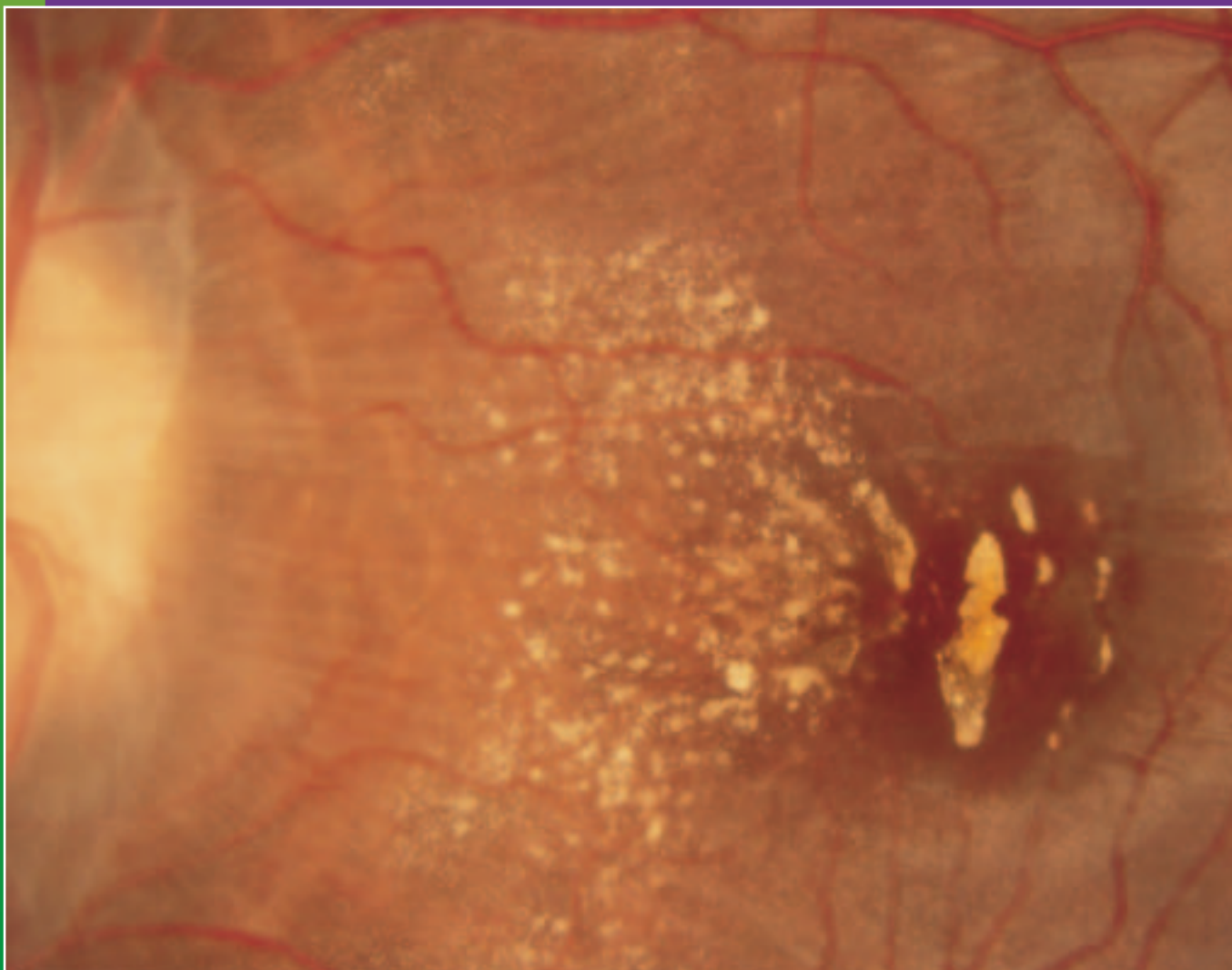


The Journal of Ophthalmic Photography



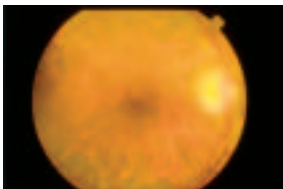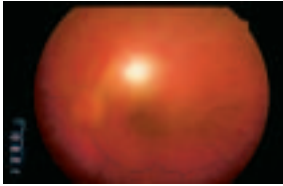
Volume 19 Number 3
December 1997

The Journal of Ophthalmic Photography



Volume 19 Number Three December 1997

ARTICLES



CASE REPORT: Toxoplasmosis Diagnosis

Chris J. Barry, CRA,

Ian J. Constable, FRACO, FRACS,

Frank V. Shilton **84**

ARTICLE: Scanning Laser Ophthalmoscope Imaging of Age

Related Macular Degeneration and Neoplasms

Linda M. Kelley, CRA, COA,

Joseph P. Walker, M.D,


Glenn L. Wing, M.D.,

Paul A. Raskauskas, M.D. **89**

CALENDAR **101**
INSTRUCTIONS TO AUTHORS **102**
LETTER FROM THE EDITOR **86**
LETTER TO THE EDITOR **86**
OPTIMAL DIGESTED **96**
PATIENT CARE CORNER **98**
FINANCE 101 **87**

About the Cover

"OPTIC NEUROPATHY": *Louise Holden, CRA, Houston Eye Associates
 First Place, 1997 Scientific Exhibit
 Fundus Photography, High Magnification*



Under suspicion of a brain tumor, this male adolescent Caucasian underwent an MRI which revealed no problems. The image was exposed using a Zeiss Fundus Camera with a 2X converter at the Baylor College of Medicine in Houston, Texas.