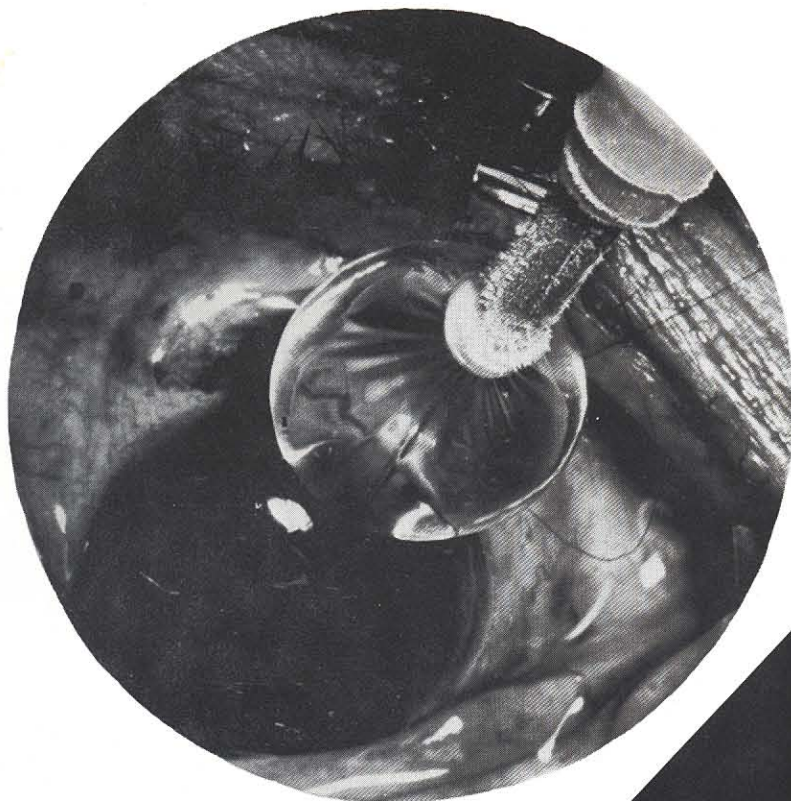




the Journal of
**Ophthalmic
Photography**

Vol. 2, No. 2 December 1979



RETINOCHOROIDITIS

VIRUSES

Cytomegalovirus
Herpes simplex
Varicella-Zoster

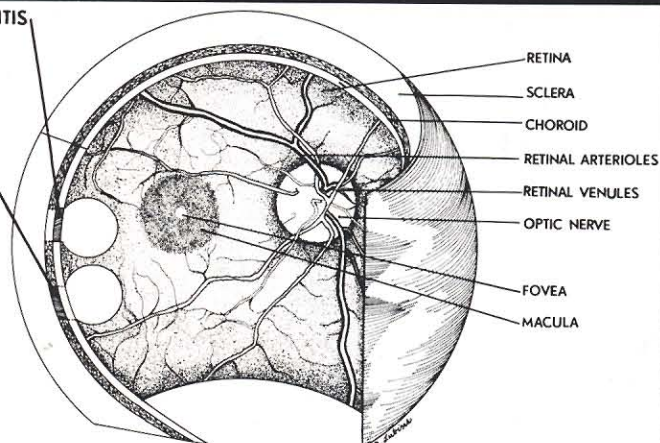
PARASITES

Toxoplasma

CHORIORETINITIS

FUNGI

Candida
Aspergillus
Cryptococcus
Nocardia





the Journal of
**Ophthalmic
Photography**

Vol. 2, No. 2 December 1979

CONTENTS

DIRECTORS

Earl A. Choromokos, F.O.P.S.
Assistant Professor
Department of Ophthalmology
University of Cincinnati College of Medicine
231 Bethesda Ave.
Cincinnati, Ohio 45267
(513) 872-5151

Kenneth E. Fong
Department of Ophthalmology
Cornet University Medical College
1300 York Ave.
New York, N.Y. 10021
(212) 472-5814, 5910

Ditte S. Jacobsen
Bascom Palmer Eye Institute
900 N.W. 17th
Miami, Fla. 33161
(305) 547-5681

John L. Johnson
Technical Director
Ophthalmic Services
William Beaumont Hospital
3601 W. 13 Mile Road
Royal Oak, Mich. 48072
(313) 288-7130

Terrance L. Tomer, F.O.P.S.
Diagnostic Photography
Wills Eye Hospital
1601 Spring Garden Street
Philadelphia, Pa. 19130
(215) 972-6277

Barrett P. Walker
Instructor in Ophthalmology
Cullen Eye Institute
Baylor College of Medicine
6501 Fannin Street
Houston, Texas 77030
(713) 790-5938

FEATURES:

Cross index filing system before and after computerization

Carl Kittelson 71

Specular photomicrography of the corneal endothelium

Jamie Nicholl 73

The Pomerantzeff Equator-Plus Camera

Martin Rothenberg and Mark Bernstein 84

Before retinal examination and fundus photography:
Taking the patient step-by-step from waiting room
to examining chair

Dorothy A. Fong, C.O.A. 90

Documentation of corneal epithelial healing rates with
the photo slit lamp

Martin Shuer 93

Improving the quality of fluorescein angiographic
negatives: suggestions for beginners and others

Terry George, RBP, FBPA 101

IMAGES:

Doris Cubillas, Thomas C. Quirk and Emery E. Billings

..... 81

CASE PRESENTATION:

Histo-chemical analysis of ghost cell glaucoma

Stephen Bloomfield, M.D. 89

EDITORIAL:

Kenneth E. Fong 70

INTERNATIONAL SECTION:

Historical review of the retinal camera in Japan

Sadao Kanagami 78

Simultaneous bilateral fluorescein angiography with
two retinal cameras

Albert Aan de Kerk, Balint Kovacs, M.D. and Wim
van Wichen 95

ON THE COVER:

Sample illustrative & photographic work produced
by The Medical Photography Department of the
New York Eye & Ear Infirmary, New York City.

Courtesy of *Infections in the abnormal host*, copyright__ Yorke Medical Book,
1980.